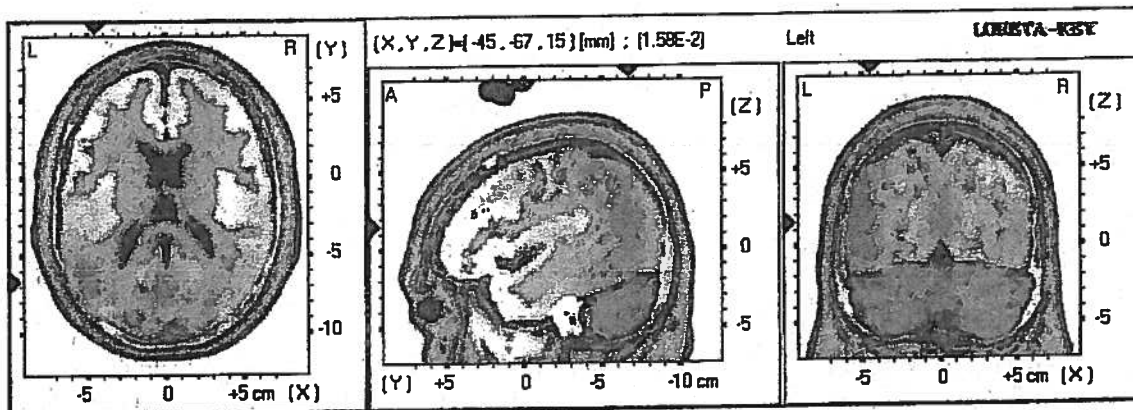
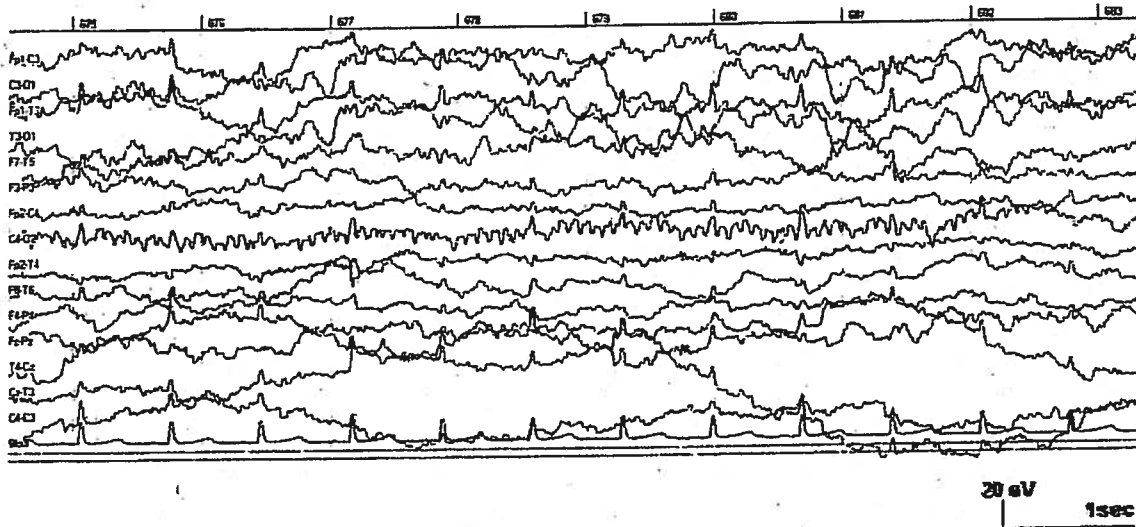


Participant Name: Jahn M. Math

### 8. Fragment-8



Value= 3.65E+1

(X= -50 , Y= -75 , Z= 30) (MNI coords)

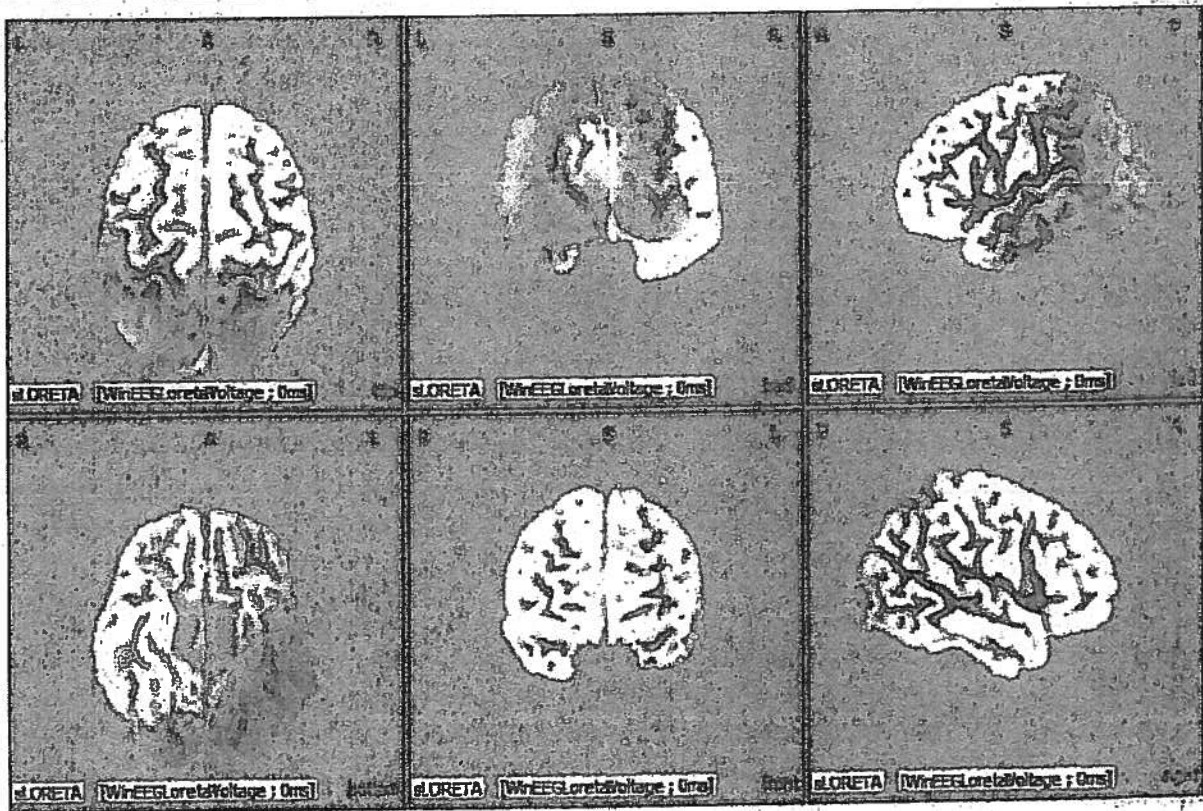
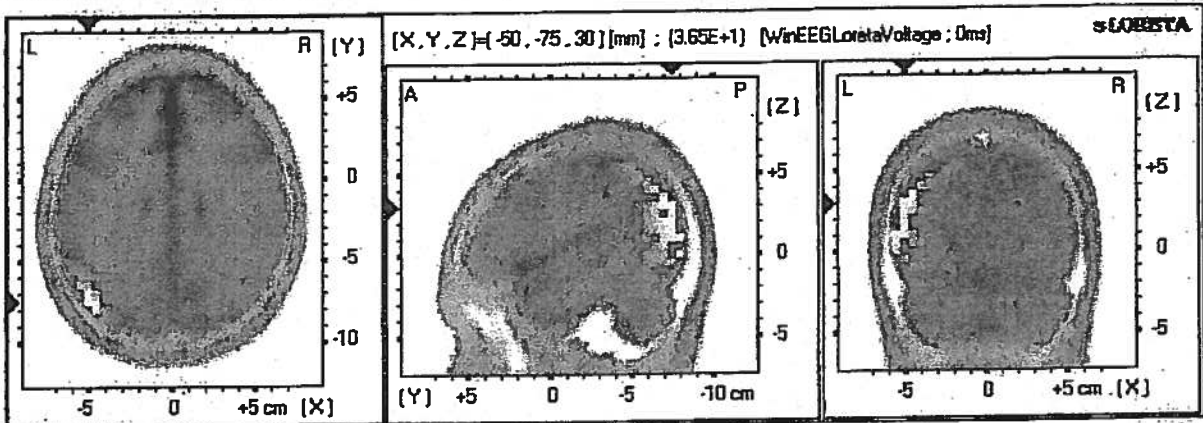
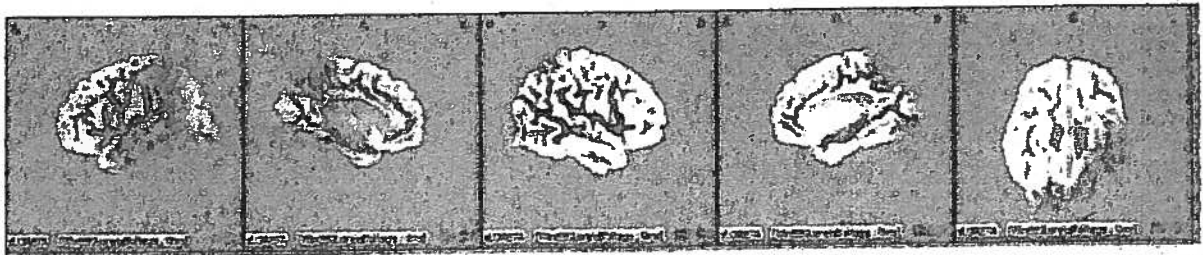
Best Match at 0 mm

Brodmann area 39

Angular Gyrus

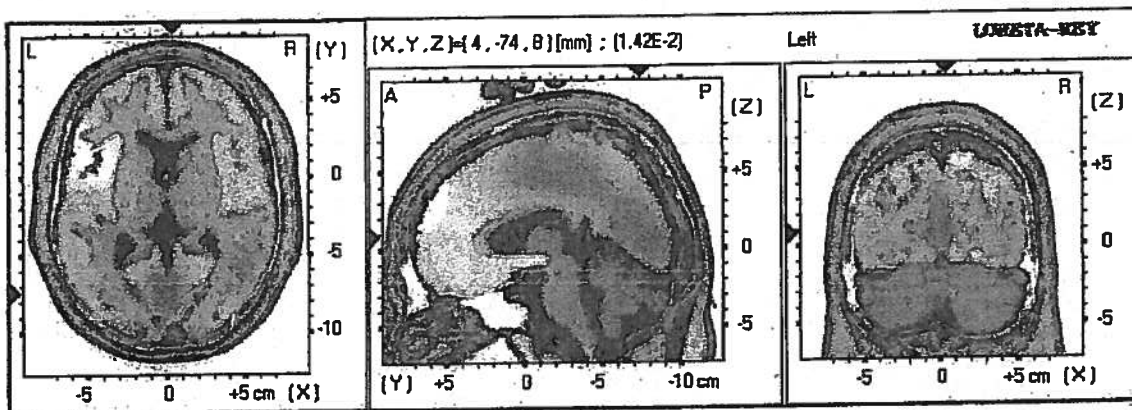
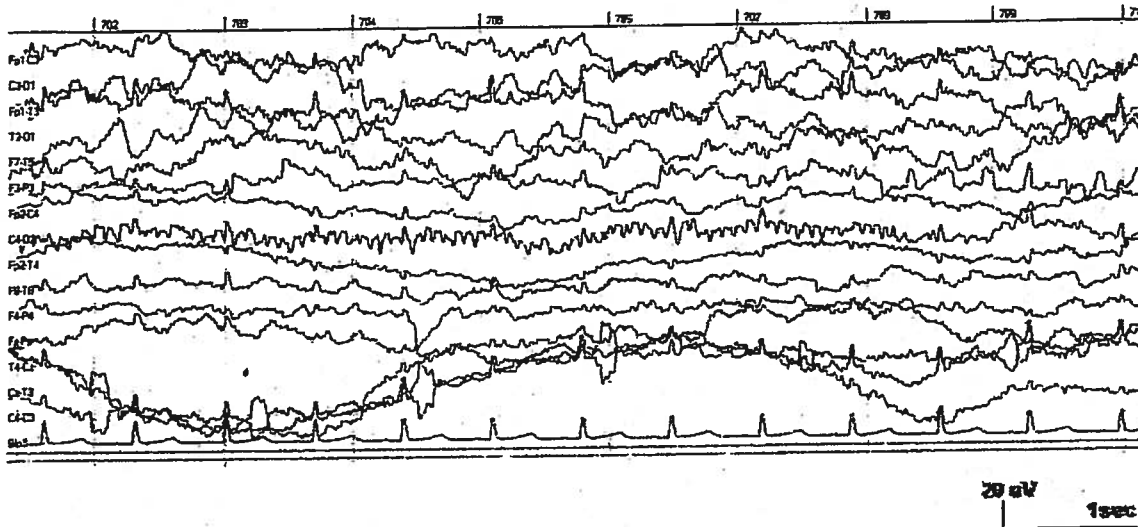
Temporal Lobe

*Patent's Name: John Mc Math*



Parent's Name: John McMath

9. Fragment-9



Value= 2.85E+1

(X= -40 , Y= -40 , Z= 60) (MNI coords)

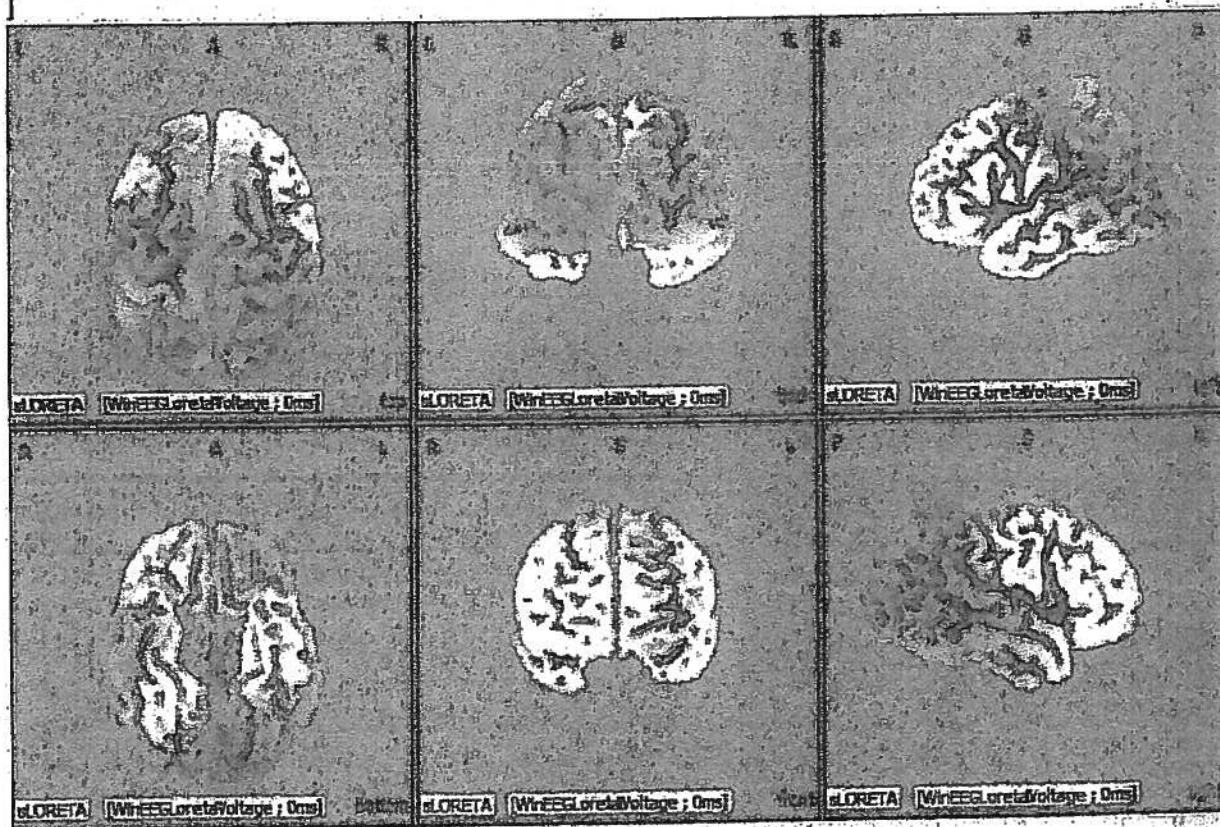
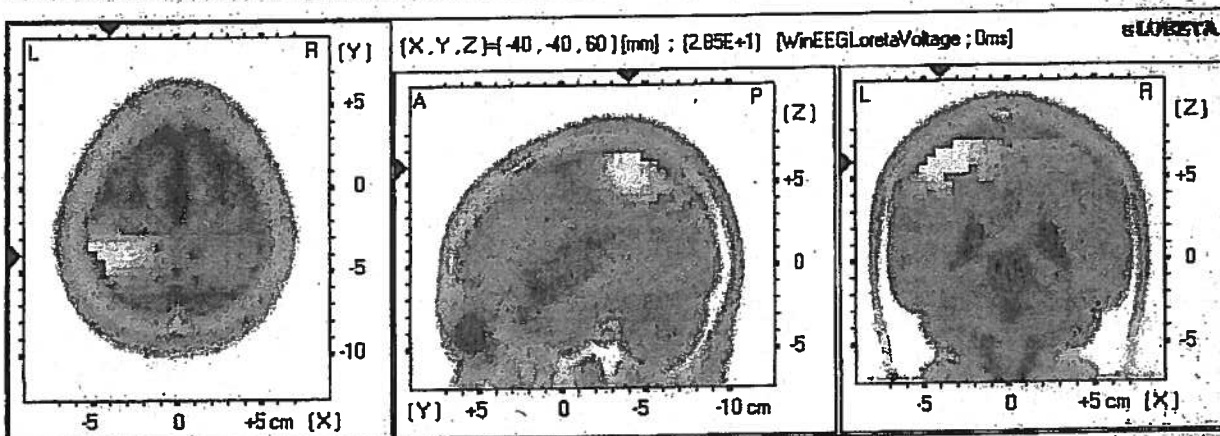
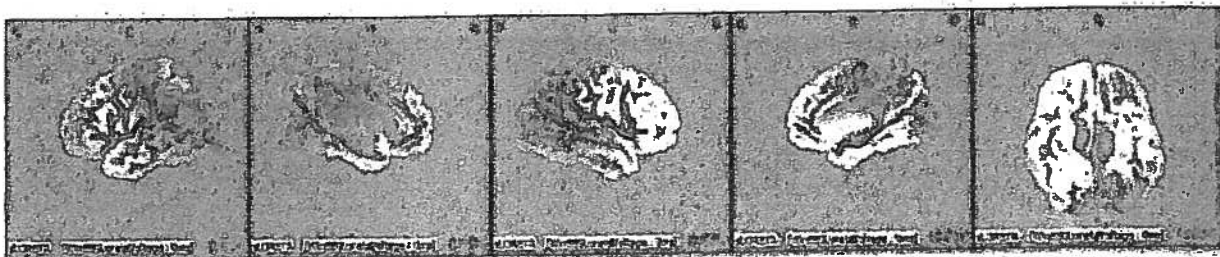Best Match at 0 mm

Brodmann area 2

Postcentral Gyrus

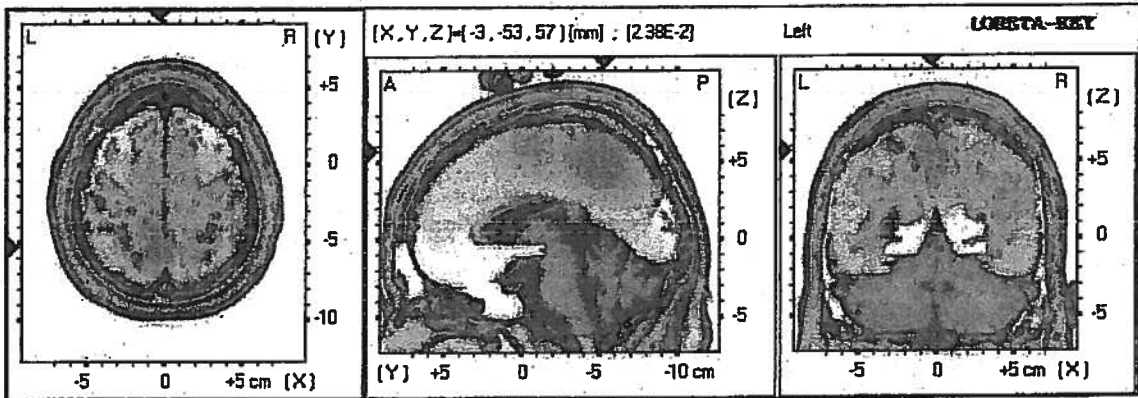
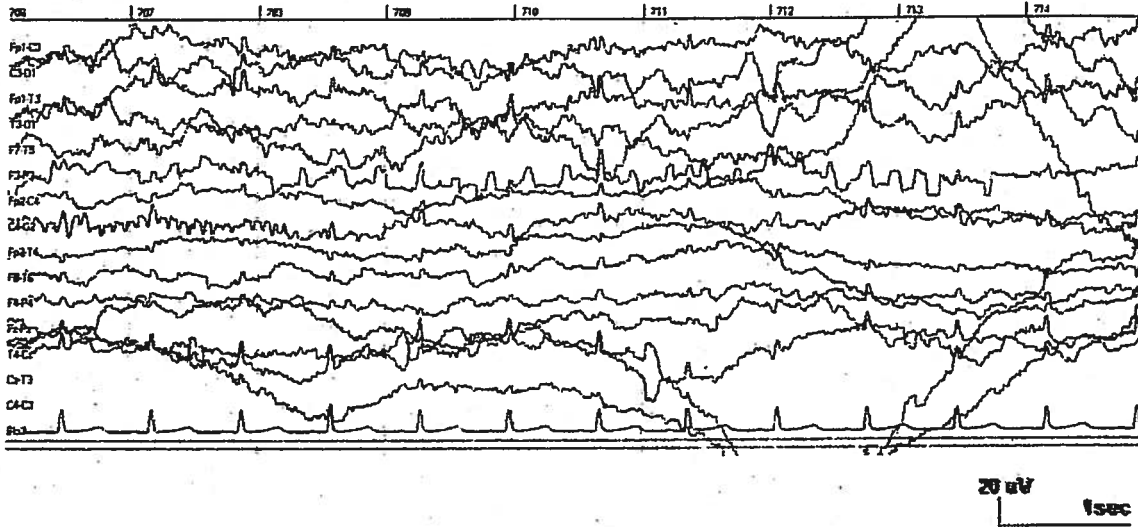
Parietal Lobe

Patent Case: Jabi McMath



Authors: Andrew J. Jeff McMath

10. Fragment-10



Value= 9.43E+1

(X= 5 , Y= -65 , Z= 65) (MNI coords)

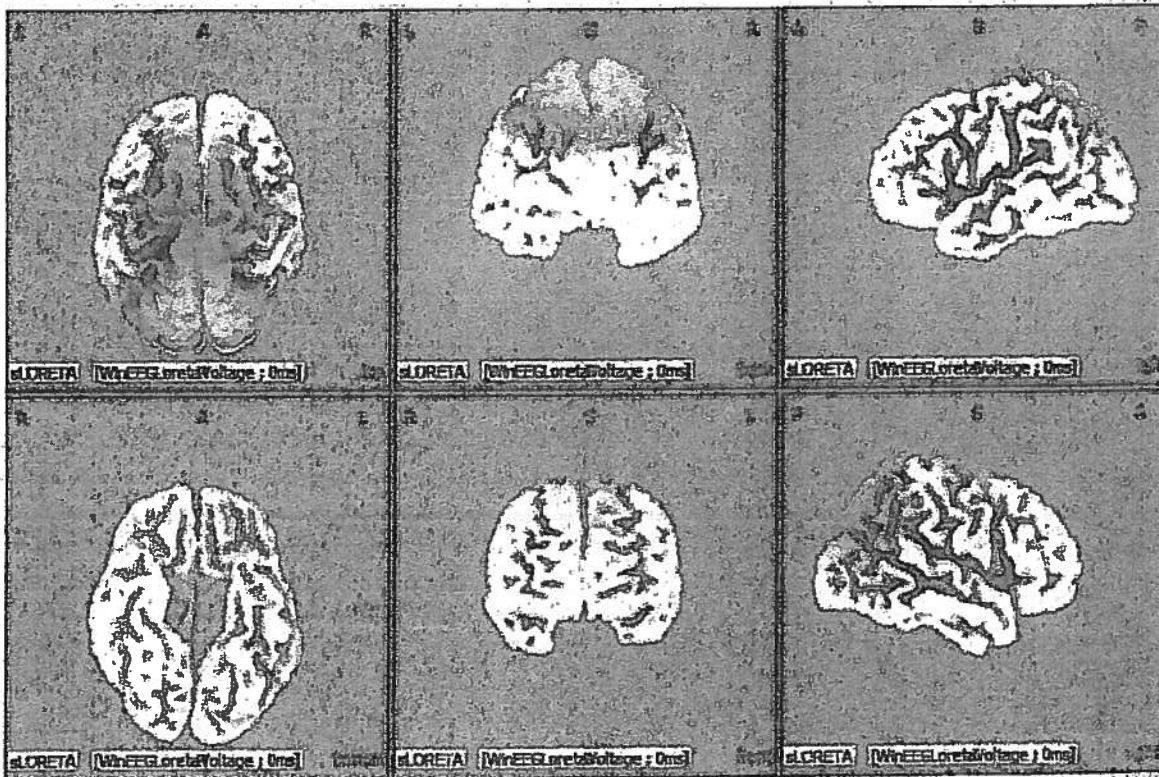
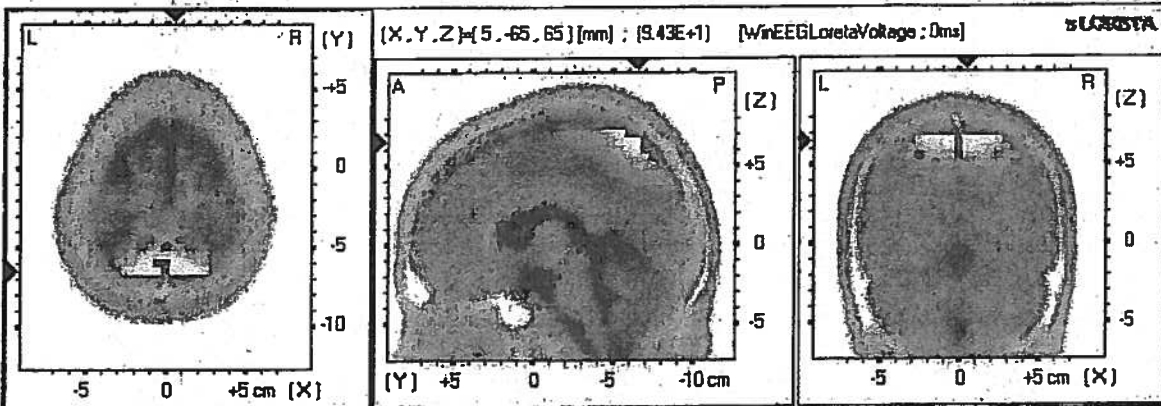
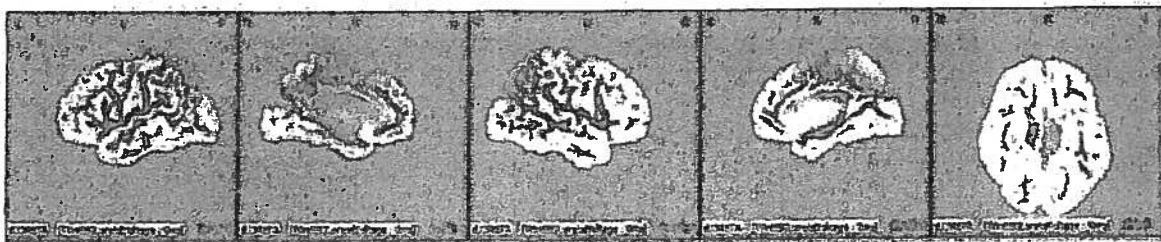
Best Match at 0 mm

Brodmann area 7

Precuneus

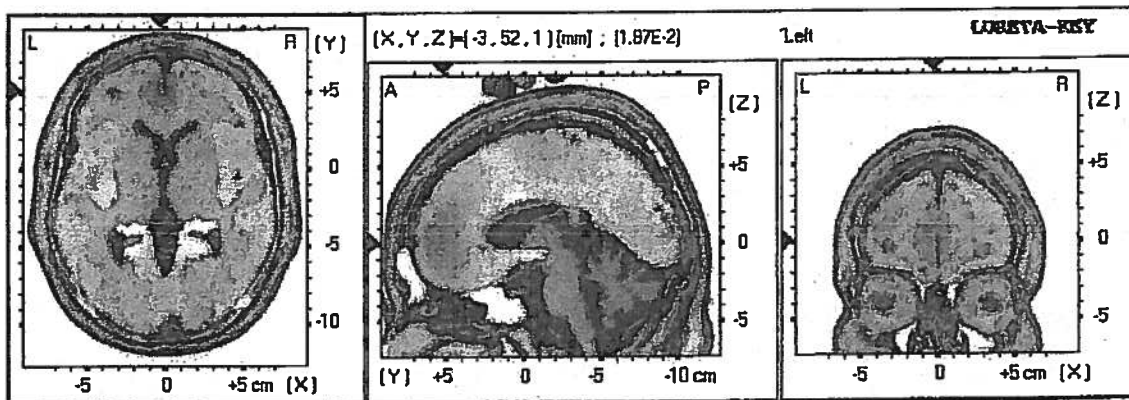
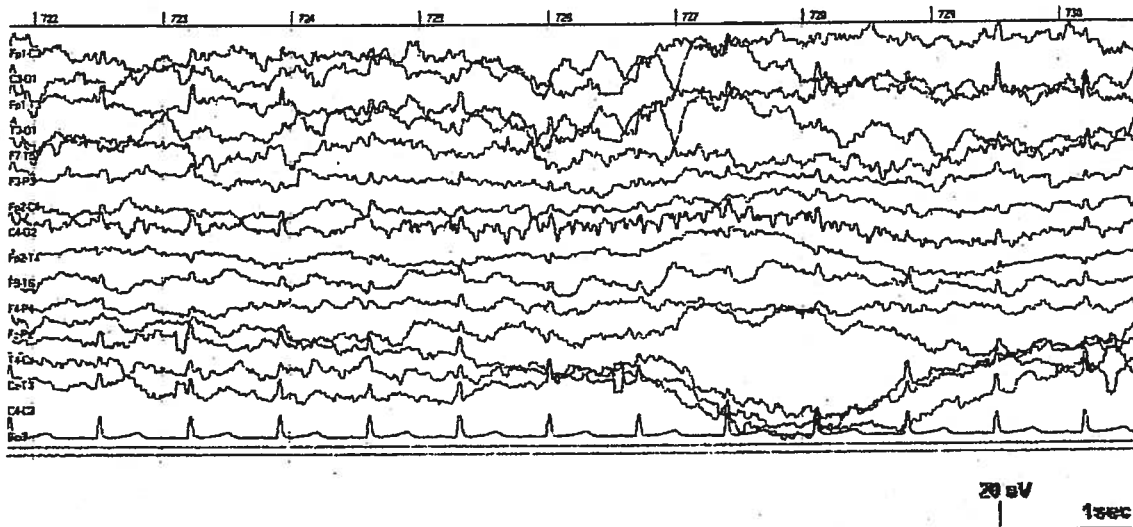
Parietal Lobe

Patient's Name: Juhli McMath



Professor James John McMath

11. Fragment-11



Value= 8.20E+1

(X= -35 , Y= 60 , Z= -10) (MNI coords)

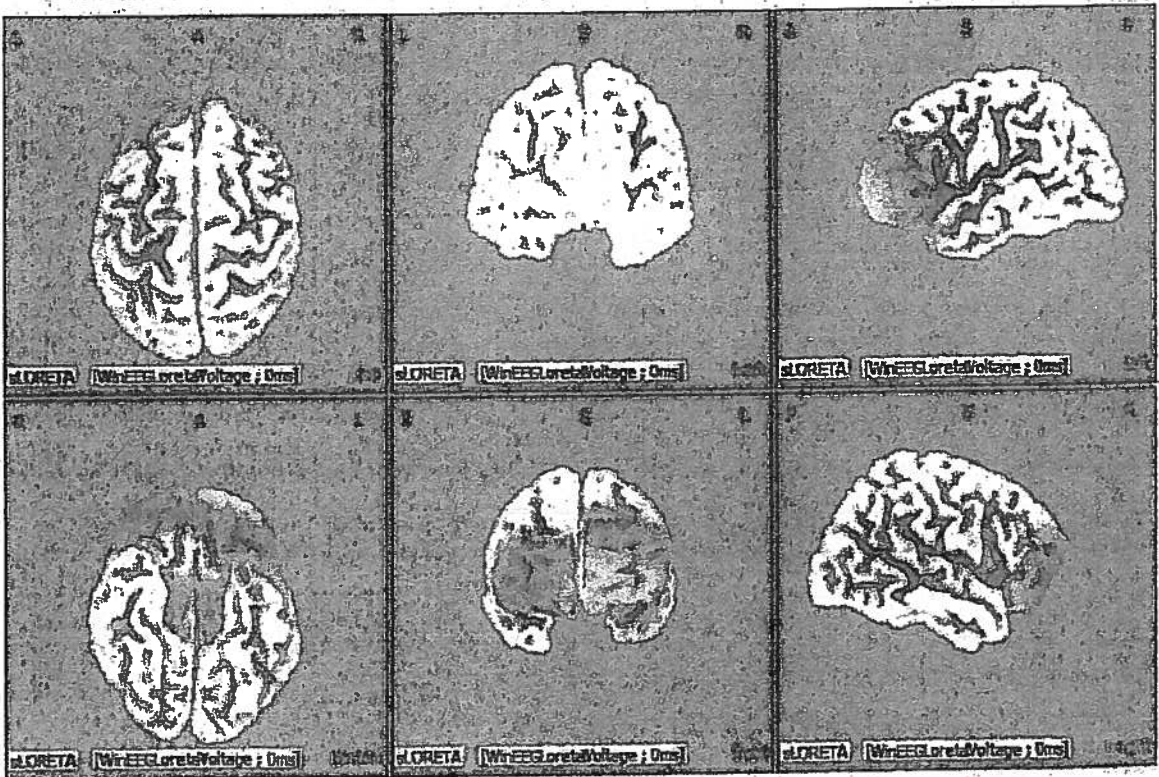
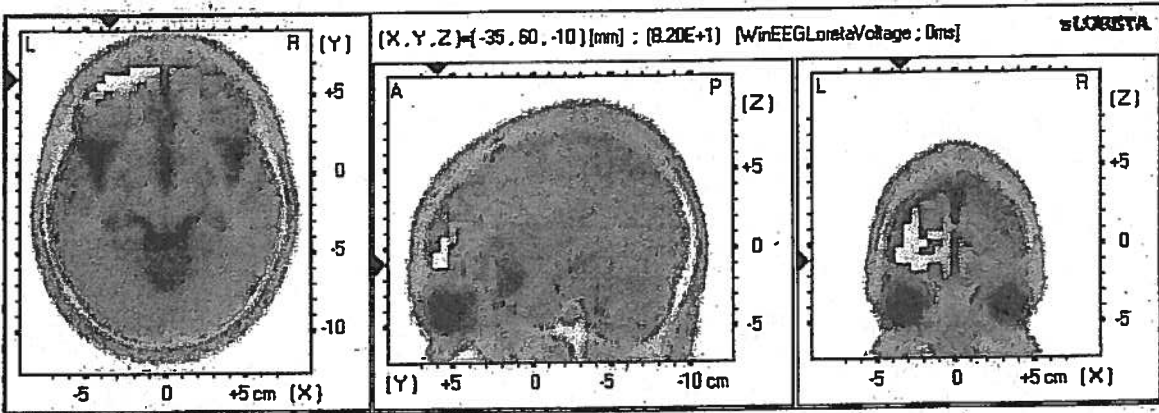
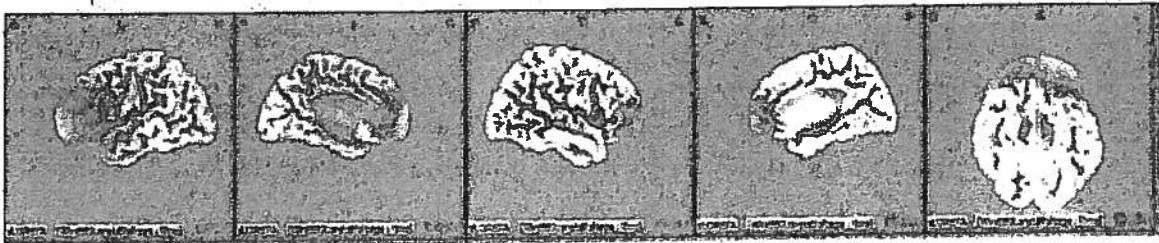Best Match at 0 mm

Brodmann area 11

Middle Frontal Gyrus

Frontal Lobe

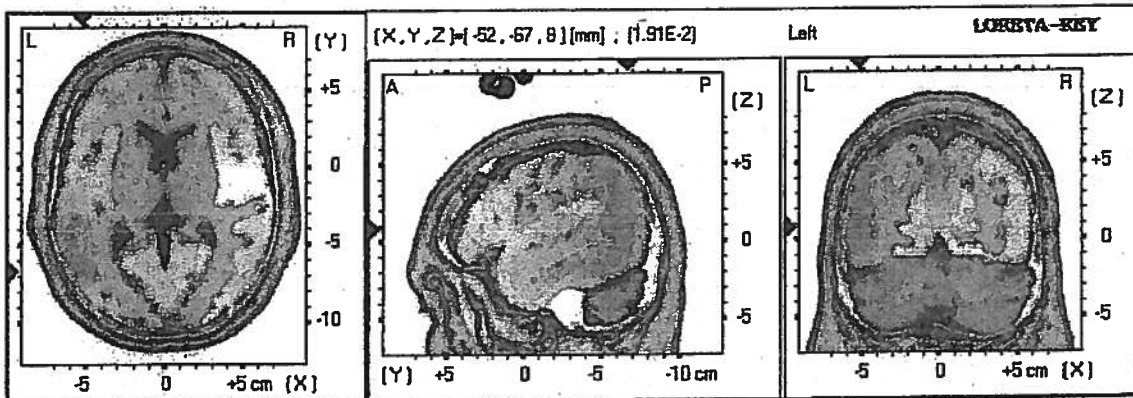
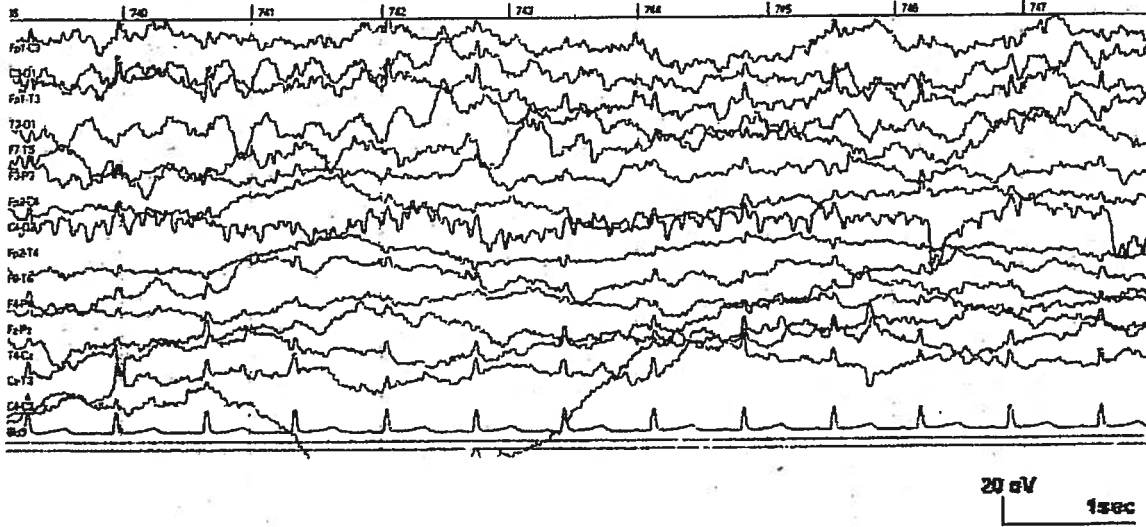
*Dr. John M. ... John McMath*





Patient Name: John McMath

12. Fragment-12



Value= 9.04E+1

(X= -5 , Y= 65 , Z= -15) (MNI coords)

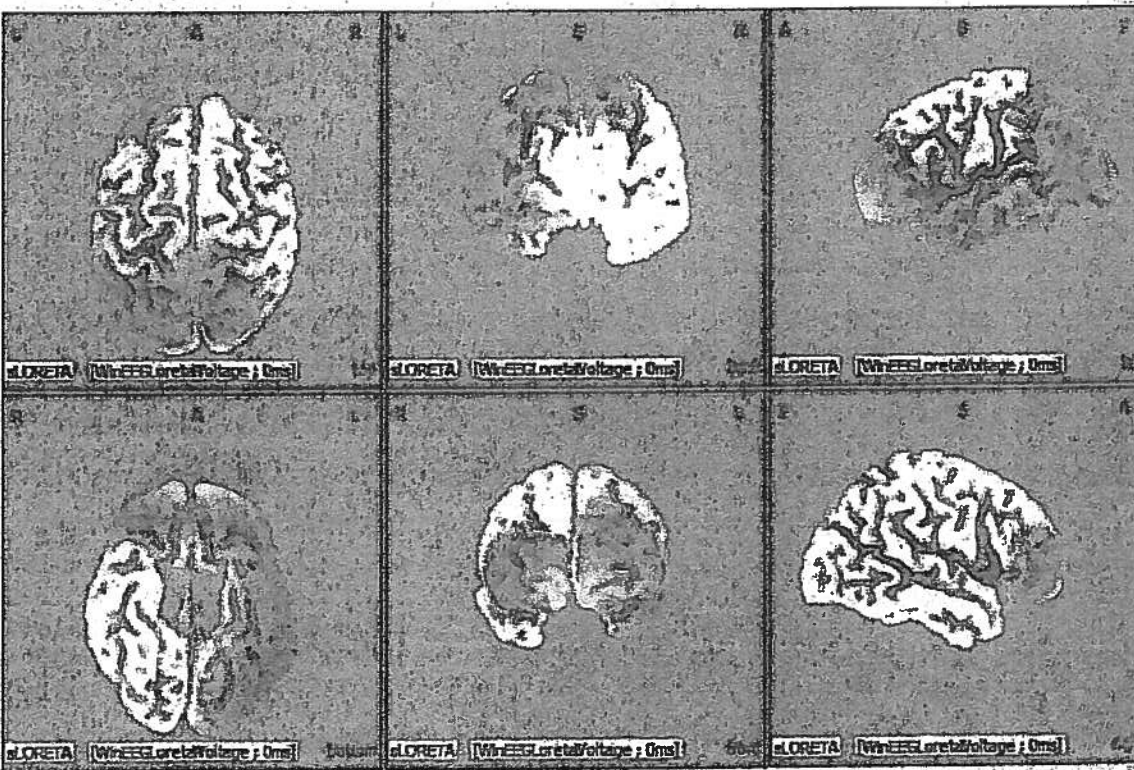
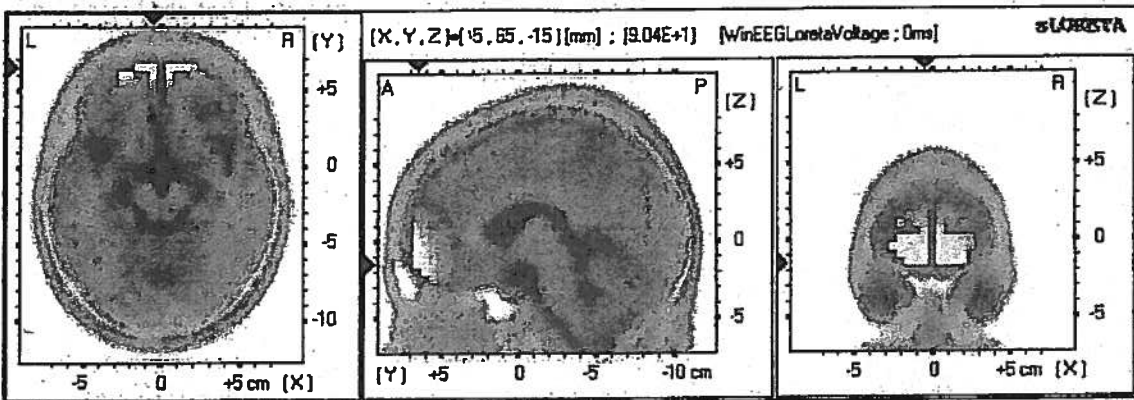
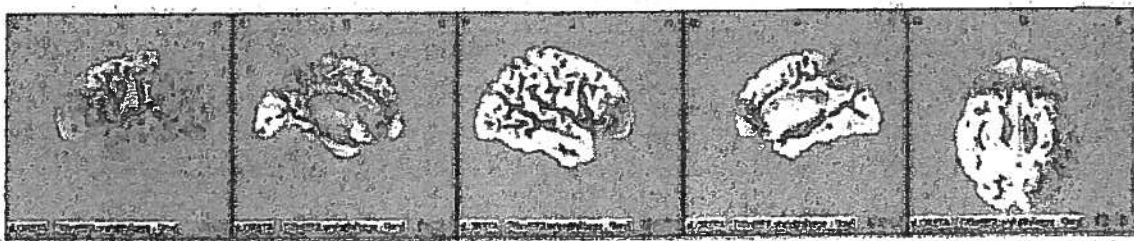
Best Match at 0 mm

Brodmann area 11

Medial Frontal Gyrus

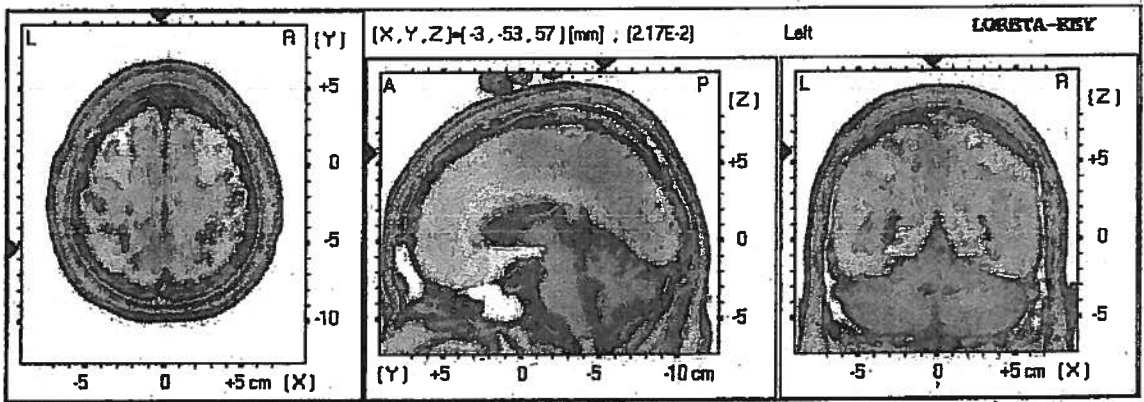
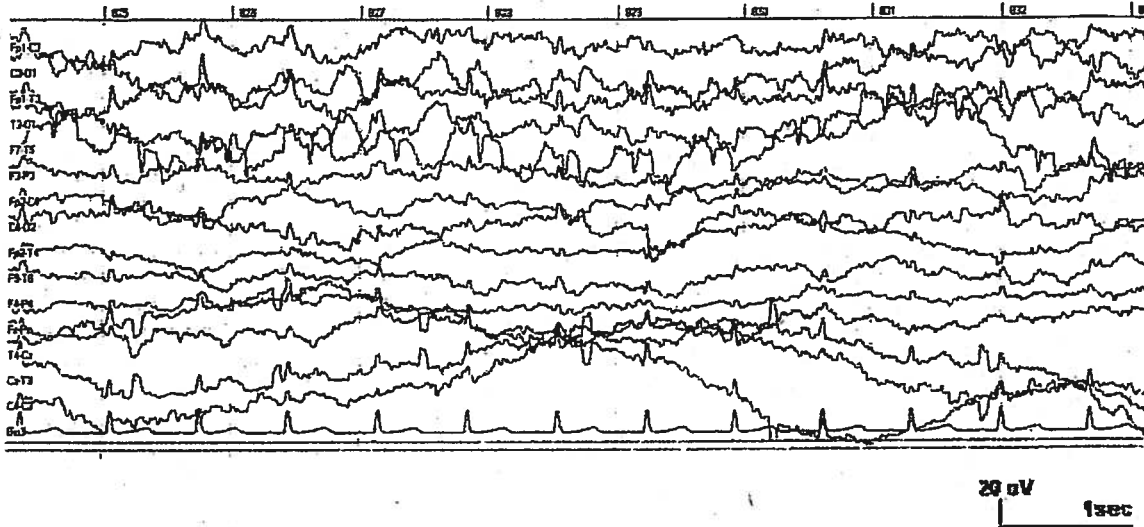
Frontal Lobe

*Patricia Ann McMahon*



Fragment-13

13. Fragment-13



Value= 7.82E+1

(X= 10 , Y= -60 , Z= 70) (MNI coords)

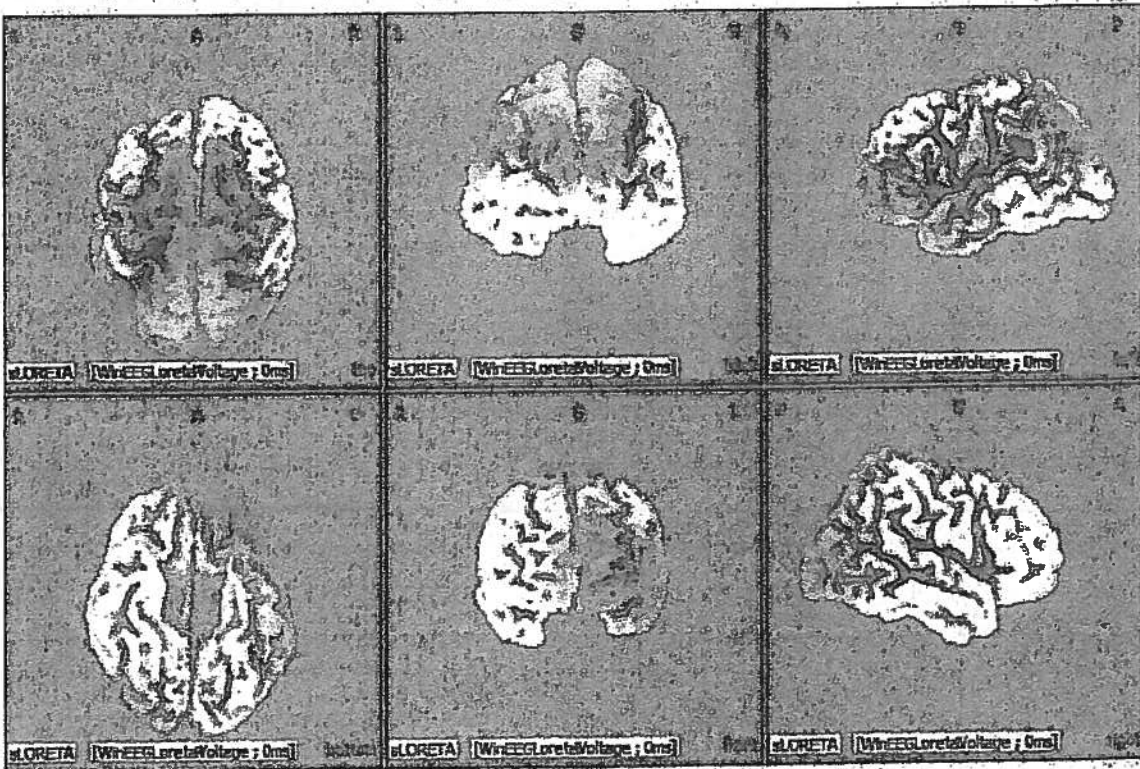
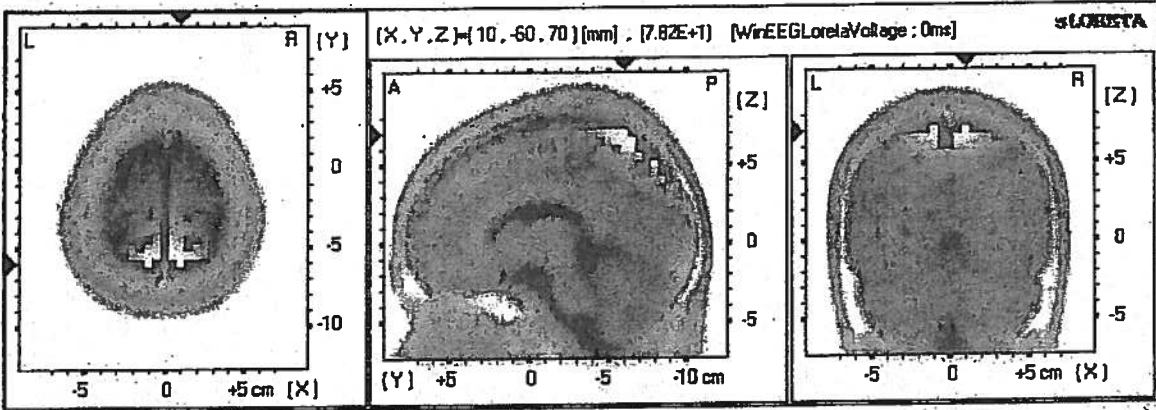
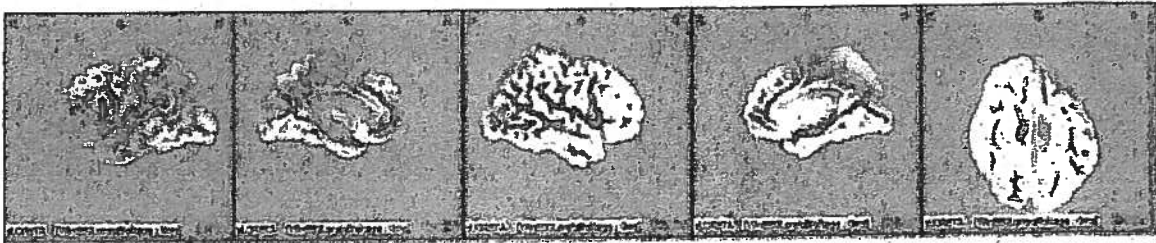
Best Match at 0 mm

Brodmann area 7

Postcentral Gyrus

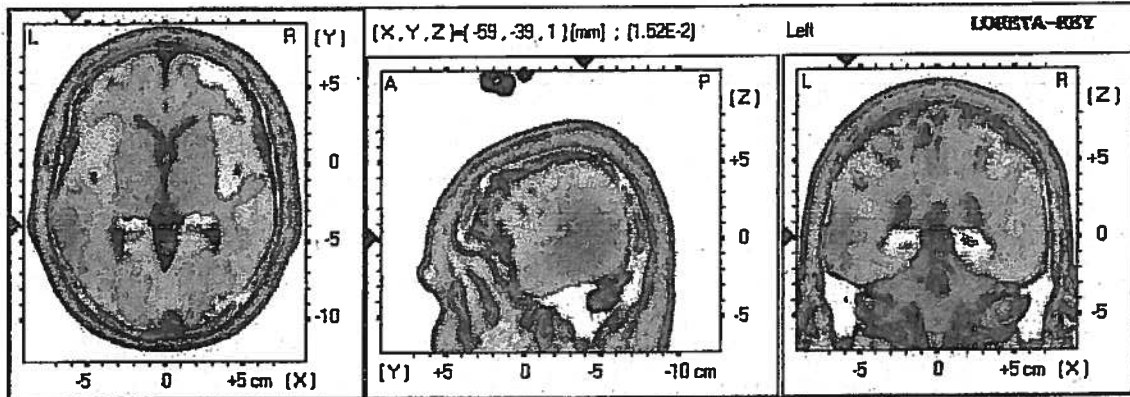
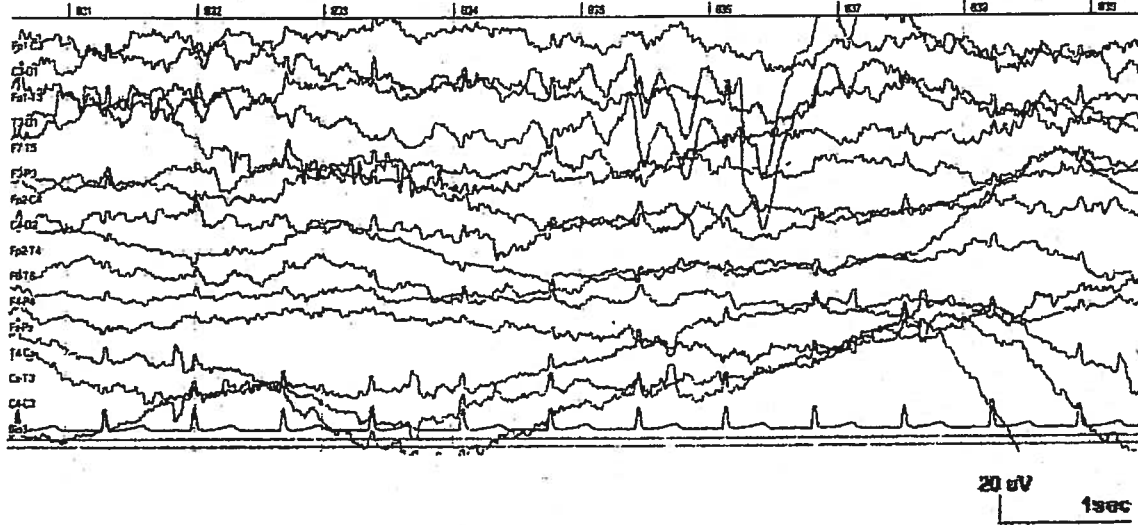
Parietal Lobe

Patient Name: John McMath



Patent's Name: John McMath

14. Fragment-14



Value= 5.08E+1

(X= -10 , Y= -100 , Z= 10) (MNI coords)

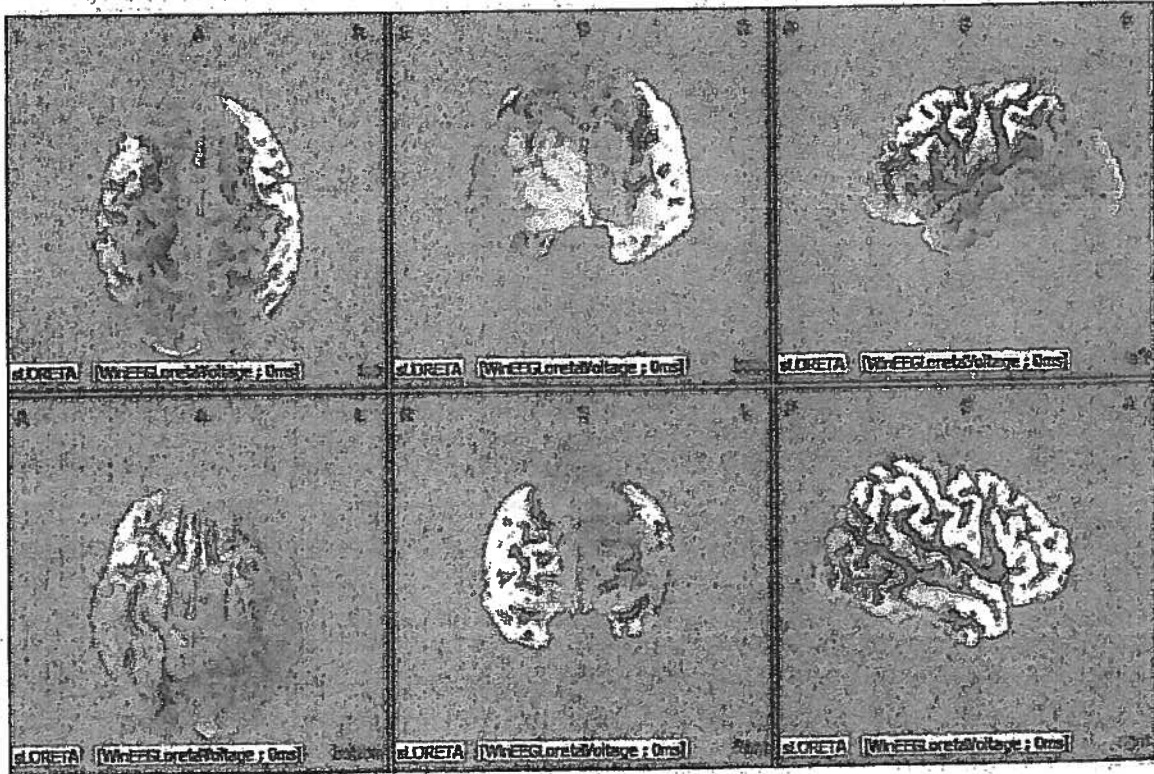
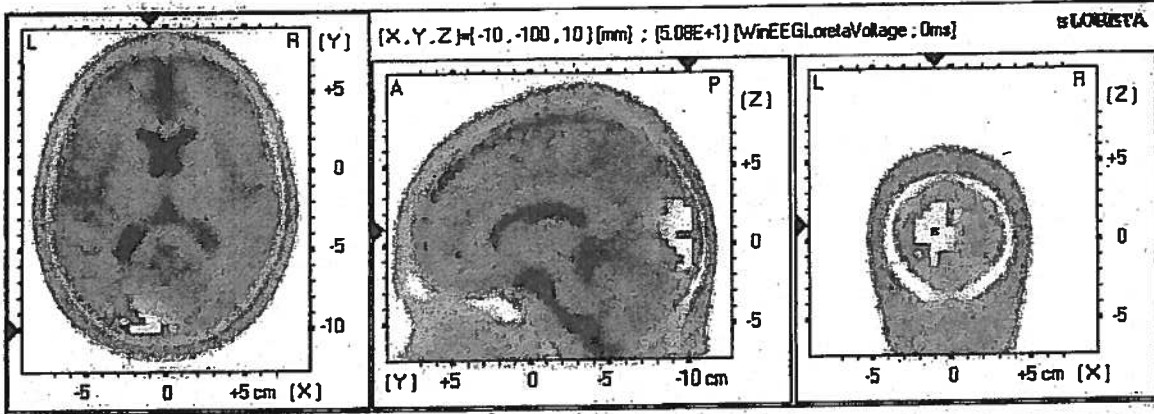
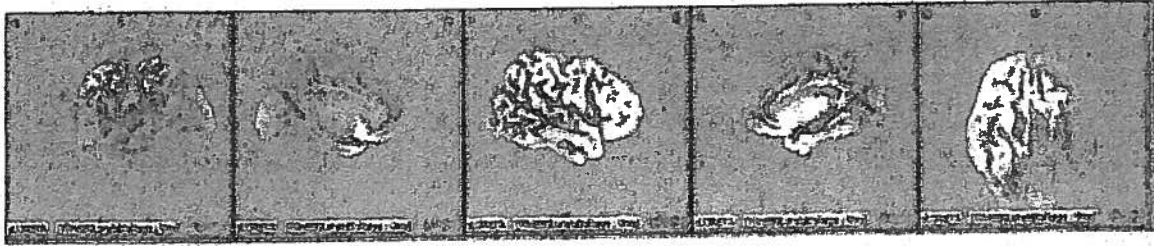
Best Match at 0 mm

Brodmann area 18

Middle Occipital Gyrus

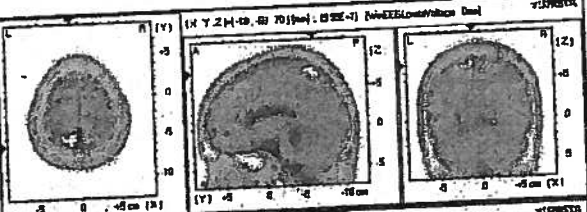

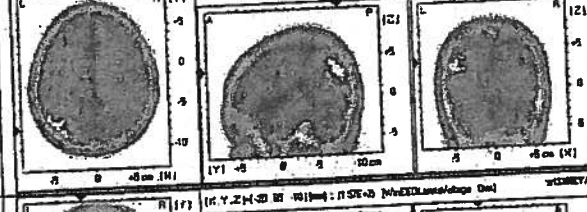

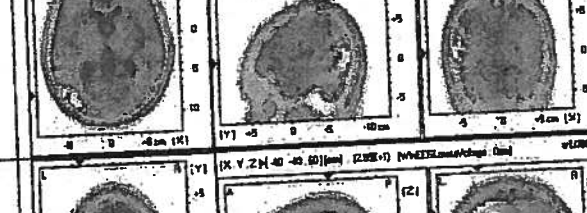

Occipital Lobe

Patent No. 7,411,111



*Patron: Name: Jatri McMath*

**Table 1. Distribution of maximal electro-cortical activity.**

#	Source Localization	Brodmann Area	Image	Recording Fragment
1	Postcentral Gyrus Parietal Lobe	Brodmann area 7		1, 10, 13
2	Lingual Gyrus Occipital Lobe	Brodmann area 18		2, 14
3	Angular Gyrus Parietal Lobe	Brodmann area 39		3, 8
4	Superior Frontal Gyrus Frontal Lobe	Brodmann area 11		4, 5, 11, 12
5	Middle Occipital Gyrus Occipital Lobe	Brodmann area 19		6, 7
6	Postcentral Gyrus Parietal Lobe	Brodmann area 2		9

*Patient's Name: Juhi McMuth*

**In summary:**

The EEG recordings were performed in accordance with Minimum Technical Standards for EEG Recording in Suspected Cerebral Death (American Clinical Neurophysiology Society).

**Specifically,**

1. A minimum of eight electrodes and reference electrodes to cover the major brain areas;
2. Interelectrode impedances under 10,000 ohms but over 100ohms;
3. Integrity of the entire recording system;
4. Interelectrode distances of at least 10 cm to enlarge the amplitudes and pick up electrical fields originating in deep structures.
5. Sensitivity increase up to 20uV/cm during most of the recording to distinguish ECS from low-voltage output EEG;
6. Time constant of 0.3-0.4 second;
7. Simultaneous ECG recording;
8. The length of the recording is no less than 30 minutes.

The patient's recordings were presented with a low-voltage output EEG.

The recordings show prevalence of diffuse Delta with superimposed activity within Alpha and low Beta ranges.

Some intermittent Theta and Alpha activity is present in a random (here and there) pattern.

The areas of maximum electrocerebral activity were identified through visual inspection of the recordings and Low Resolution Brain Electromagnetic Tomography (Loreta) algorithm.

The summarized results are presented in Table 1. The analysis shows that areas with maximal electro-cerebral activity (mostly within Theta range) were better expressed on the left and primarily include fronto-parietal-occipital cortexes.

No response to intermittent photic stimulation (6-16 Hz) was registered.

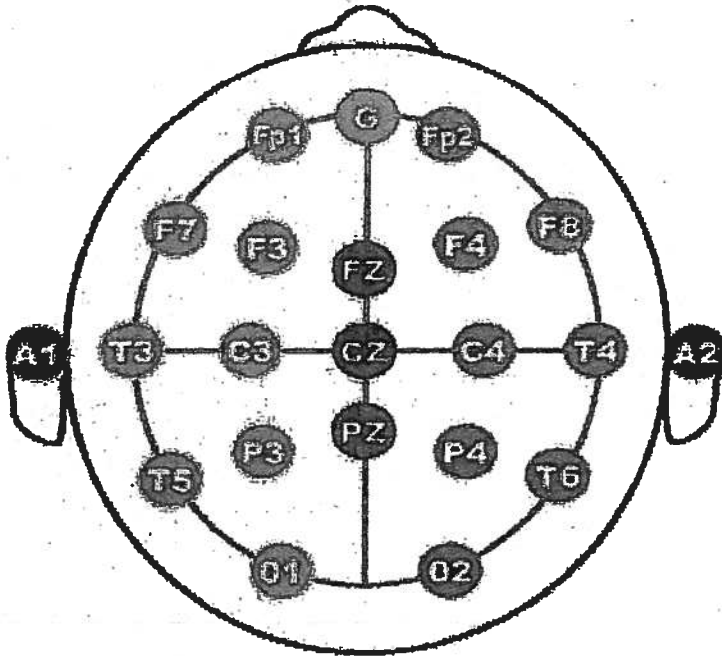
Report provided by Clinical Psychologist Elena B. Labkovsky, Ph.D., BCIA-EEG

---



Psychiatrist: J. J. McMurphy

**Appendix 1.**



The letters used are:

- F - Frontal lobe
- T - Temporal lobe
- C - Central lobe
- P - Parietal lobe
- O - Occipital lobe

"Z" refers to an electrode placed on the mid-line.

**Appendix 2.**

